

## Comparative Evaluation of Effectiveness of Pinhole Surgical Technique Versus Coronally Advanced Flap with PRF as an Adjunct in the Management of Gingival Recession Defect- A Randomised Controlled Clinical Trial

Meghna Jassi<sup>1</sup> | Navneet Kaur<sup>2\*</sup> | Gurpreet Kaur<sup>3</sup> |

1. PG Student, Department of Periodontology and Oral Implantology, National Dental College and hospital, Dera Bassi, Punjab, India.
2. Reader, Department of Periodontology and Oral Implantology, National Dental College and Hospital, Dera Bassi, Punjab, India.
3. Professor and HOD, Department of Periodontology and Oral Implantology, National Dental College and Hospital, Dera Bassi, Punjab, India.

**\*Corresponding Author:** Navneet Kaur, Reader, Department of Periodontology and Oral Implantology, National Dental College and Hospital, Dera Bassi, Punjab, India.

doi: 10.71168/NDO.03.02.146

**Received Date:** March 20- 2026

**Publication Date:** April 29- 2026

### Abstract

**Introduction:** The primary goal of periodontal therapy is to ensure the long-term health and functionality of the dentition while addressing aesthetic concerns. Modern oral therapy emphasizes preserving existing structures over replacing them, aligning with the minimally invasive surgery (MIS) approach. Aesthetic considerations, such as the management of exposed roots visible during smiling, have gained prominence as patients increasingly prioritize their aesthetic appearance. Among the advancements in mucogingival therapy, the Pinhole Surgical Technique (PST), introduced by John Chao, has emerged as a transformative procedure for managing marginal tissue recession (MTR), particularly Miller's Class I and II cases. Studies in the literature have shown 94% mean defect reduction with PST, highlighting its effectiveness and predictable clinical outcomes. PST stands out for its simplicity, patient comfort, and reliable aesthetic results, making it a promising innovation in periodontal plastic surgery.

**Aim and Objectives:** 1. To assess the effectiveness of platelet-rich fibrin (PRF) used in the Pinhole Surgical Technique in comparison with the Coronally Advanced Flap for the management of gingival recession defects 2. To compare the clinical outcomes of the Pinhole Surgical Technique and Coronally Advanced Flap with respect to recession depth, recession width, keratinized gingival width, and gingival thickness.

**Materials and Methods:** Twenty patients within the age range of 30–50 years, presenting with Class I or Class II gingival recession, were randomly recruited and divided into two groups with 10 patients in each group: Group 1 (test group) included patients treated with the Pinhole Surgical Technique along with placement of platelet-rich fibrin, while Group 2 (Control Group): included patients treated with Coronally advanced flap surgery with a placement of Platelet rich fibrin. Recession depth (RD), recession width (RW), width of keratinized gingiva (WKT), probing pocket depth (PPD), and clinical attachment level (CAL) were measured at baseline and 3 months postoperatively.

**Results:** No statistically significant differences were observed between the groups in terms of width of keratinized gingiva (WKG), probing pocket depth (PPD), and clinical attachment level (CAL) at baseline and after 3 months.

**Conclusion:** The findings suggest that both the Pinhole Surgical Technique combined with PRF and the Coronally Advanced Flap with PRF are effective treatment modalities for Miller's Class I and II gingival recession defects.

**Keywords:** Pinhole Surgical Technique, Coronally Advanced Flap, Gingival Recession, Platelet rich Fibrin, recession defect, Minimal invasive technique.

## Introduction

Periodontal therapy primarily aims to maintain and enhance periodontal health and the functional longevity of the dentition while addressing aesthetic concerns, which are inseparably linked to patient satisfaction. Modern oral therapies, including minimally invasive surgical approaches emphasize both functional outcome and preservation or improvement in terms of aesthetic outcome. A contemporary concept for periodontal care is the preservation of existing tissues resulting in arise of minimally invasive surgical technique (MIST). One notable advancement is Pinhole Surgical Technique (PST) which was introduced by John Chao in 2012 [1]. PST offers a revolutionary approach to managing marginal tissue recession (MTR), particularly Miller's Class I and II gingival recession defect and are often associated with exposed root surface that may results in compromised aesthetics. In today's world, Patients are more aware of their aesthetic appearance which have direct visible impact of gingival recession on their smile and has led to driven a demand for minimally invasive and aesthetically pleasing approaches.

Traditional methods for treating MTR have included a range of surgical procedures such as the laterally positioned flap, free gingival graft (FGG), connective tissue graft (CTG), and coronally advanced flap (CAF) often combined with regenerative therapies like platelet-rich plasma (PRP) and platelet-rich fibrin (PRF) [2]. While these techniques are effective and predictable and each technique have its own unique indications, advantages, and limitations. For example, free gingival graft requires suturing and grafting results in an extended recovery time period and potential complications by creating a second surgical site for grafting. Over the past three decades, there has been significant evolution in treatment approaches culminating in the current era of minimally invasive techniques which prioritize patient comfort, faster recovery, and optimal aesthetic results.

The Pinhole Surgical Technique involves the creation of a small pinhole in the existing gingival tissue using a specialized instrument. Through this pinhole, specialized tools are used to gently loosen and reposition the gingival tissue and covering the exposed root surfaces and restoring the tissue in a more natural way. This technique eliminates the need for sutures, grafts or additional incisions making it less invasive than traditional methods. Literature studies on PST have demonstrated a mean recession defect reduction of 94%, highlighting its predictability and clinical effectiveness [1]. Furthermore, PST is associated with minimal postoperative discomfort, shorter recovery time and high patient satisfaction due to its ability to achieve desirable aesthetic outcomes without extensive surgical intervention. Preservation and minimal intervention are key principles in periodontal plastic surgery and PST aligns perfectly with these goals. As periodontal therapy continues to evolve, techniques like PST exemplify the shift towards patient-centered care that prioritizes both functionality and aesthetics. This technique has its own simplicity, combined with its ability to deliver long-lasting and natural-looking results have a promising and innovative solution in the management of MTR, addressing both clinical and cosmetic concerns with unparalleled efficiency.

Coronally advanced flap (CAF) has its own advantages as compared to other traditional techniques that include no need of a donor site and better color and contour match with the soft tissue. This technique results in an excellent aesthetic outcome and is simple to perform the technique. The Coronally Advanced Flap provides consistent root coverage outcomes in Miller Class I and Class II gingival recession defects.

[3] CAF technique can be used alone or in combination with any chosen grafting material, autologous, Xenograft or addition of biological factors such as EMD, platelet rich plasma (PRP), platelet rich fibrin (PRF) has been suggested to increase the predictability of the root coverage treatment [4,5]. PRF has been shown to be a source of transforming growth factors  $\beta$ -1 (TGF $\beta$ -1), vascular endothelial growth factor (VEGF), and platelet derived growth factor (PDGF). PRF is characterized by a three-dimensional fibrin architecture resulting from polymerization, serving as a reservoir for platelets, leukocytes, cytokines, and circulating stem cells.

Early preparation protocols for PRF involved high-speed centrifugation, leading to the development of a dense fibrin clot capable of functioning as a three-dimensional matrix for periodontal tissue regeneration.

However, to the best of our knowledge, there is limited data available in the literature on the use of PRF in combination with PST for the treatment of gingival recession defect and investigate the clinical outcome in terms of clinical parameters. Based on the aforementioned evidence, this clinical investigation was designed to compare the effectiveness of the Pinhole Surgical Technique and the Coronally Advanced Flap when combined with PRF in the treatment of gingival recession defects.

## Aim and Objectives

**Aim:** To evaluate the effectiveness of Pinhole Surgical Technique versus Coronally Advanced Flap with PRF as an adjunct in the management of gingival recession defect.

## Objectives

1. To evaluate the efficacy of PRF in Pinhole Surgical Technique versus Coronally Advanced Flap in the management of gingival recession defect.
2. To evaluate and compare the clinical outcome of Pinhole Surgical Technique versus Coronally Advanced Flap in terms of clinical parameters including recession depth, recession width, width of keratinized gingiva and gingival thickness.

## Materials and Methodology

---

### Source of data

For the proposed study, a total of 20 patients with age group of 30-50 years diagnosed with class I or class II gingival recession were randomly selected from the outpatient department of Periodontics and Oral Implantology. Institutional ethical approval was obtained, and informed consent (verbal and written) was taken from all patients.

### Study design

Patients were randomly selected and divided into 2 groups with 10 patients in each group:

**Group 1 (Test group):** 10 patients treated with Pin hole surgical technique with a placement of Platelet rich fibrin.

**Group 2 (Control Group):** 10 patients treated with Coronally advanced flap surgery with a placement of Platelet rich fibrin.

### Inclusion Criteria

- Patients in the age group of 30-50 years
- Presence of Miller's Class 1 or Class II gingival recession defect
- Presence of single or multiple gingival recession defect either in maxilla or mandibular area
- Patients with aesthetic concern
- Patients who were compliant with oral hygiene instructions and full mouth plaque score <1%.

### Exclusion Criteria

- Patients who failed to maintain proper oral hygiene (plaque index > 1) after phase-1 therapy
- Recession defect associated with caries and deep abrasion
- Teeth with evidence of pulpal pathology
- Pregnant and lactating women
- Smokers and tobacco chewers
- Presence of mobile teeth
- Patients who were undergone any previous periodontal surgical procedure at the involved site.

## Methodology

---

### Clinical Procedure

A total of 20 patients with age group of 30-50 years diagnosed with class I or class II gingival recession were randomly selected and divided into 2 groups with 10 patients in each group:

#### Initial therapy

Each patient received thorough information on how to practice good oral hygiene. Phase I periodontal therapy was performed across the entire mouth in both the groups.

#### PRF preparation

A standard protocol was followed for preparing PRF. Prior to the surgical procedure, 5ml blood was drawn from anti-cubital vein and gathered in sterile tubes (devoid of anticoagulant) and centrifuged at 3000 rpm for 10 minutes. This allows formation of structured fibrin clot in the center of the test tube. Sterile tweezers and scissors were used to separate the PRF from red corpuscular base. It was then compressed to squeeze out the serum and obtain a fibrin membrane.

#### Group 1 (Test group): PST+PRF

The Pinhole Surgical Technique combined with PRF was performed. After achieving local anesthesia, a 2–3 mm horizontal access point was made in the vestibular region apical to the recession defect.

A sulcular incision was placed, ensuring the interdental papillae at mesial and distal sites remained intact.

Subsequently, tunneling instruments were employed to carefully mobilize and expand the gingival tissues, facilitating their repositioning in an apico-coronal direction until they were advanced coronally beyond the cemento-enamel junction (CEJ).

The flap was further advanced coronally and laterally to enable mobilization of the neighboring papillae on both sides of the denuded root.

The use of the patented instrument was substituted as a Periostome. After periosteal elevation and careful release of muscular and fibrous adhesions, full-thickness splitting was accomplished, allowing for a tension-free and mobile gingival tissue.

Subsequently, PRF membrane were cut into small strips and inserted through the hole to the gingival margin. Gentle digital pressure was applied for 3 min to hold the gingiva in its new position.

**Group 2 (Control Group): CAF+PRF**

After the administration of local anesthesia, A coronally advanced (positioned) flap technique was performed at the surgical site. This surgical technique was defined by two oblique releasing incisions at the mesial and distal aspects and horizontal incision at the base of interdental papilla adjacent to recession. Sulcular incision was given around the affected tooth. Flap elevation was performed with an initial full-thickness reflection apical to the recession defect, followed by split-thickness dissection. Subsequently, a periosteal releasing incision was made at the base of the flap to enable passive coronal advancement without tension.

After flap elevation exposed root surfaces were scaled and root planed using ultrasonic instruments. Adjacent interdental papillae were deepithelized. The recipient site was covered by moist gauze till the PRF membrane was prepared. The flap was positioned higher to CEJ and sutured using 4-0 silk suture with continuous sling sutures coronally. The flap was secured with composite stops to prevent apical relapse of the gingival margin during initial stages of healing. A periodontal dressing - COE-PAK™ was placed on the surgical site for 1 week.

**Post operative instructions**

Post operative instructions were prescribed that include antibiotic (Amoxicillin 500 mg tds for 7 days) and NSAIDs (Ibuprofen 400 mg every 4 to 6 hours as needed). Patients were advised to use Chlorhexidine gluconate 0.2% twice a day for 15 days. Patients were advised not to brush their teeth in the treated area. Plaque control in the surgically treated area was maintained by chlorhexidine rinsing for an additional 2 weeks. The sutures and periodontal dressing were removed 14 days after surgery.

**Clinical Parameters**

Clinical parameters included the assessment of probing pocket depth (PPD), clinical attachment level (CAL), recession depth (RD), recession width (RW), width of keratinized gingiva (WKG) was recorded and evaluated at the baseline and 3 months.

**Statistical Analysis**

All the clinical parameters (PPD, CAL, RD, RW, WKG) were recorded and put to statistical analysis using the SPSS statistical software 23.0 Version. The descriptive statistics included mean and standard deviation. The intergroup and intragroup comparison for the difference of mean scores between independent groups was done using Mann Whitney U test.

**Results**

**Table 1:** Intergroup comparison of all clinical parameters in between group 1 and group 2 at baseline and after 3 months.

	Width of Keratinized Gingiva (WKG)		Recession Depth (RD)		Recession Width (RW)		Probing Pocket Depth (PPD)		Clinical Attachment Level (CAL)	
	Group 1	Group 2	Group 1	Group 2	Group 1	Group 2	Group 1	Group 2	Group 1	Group 2
Baseline	7.95±0.49	8.10±0.46	1.50±0.53	1.80±0.40	2.30±0.48	0.18±0.10	3.50±0.53	3.10±0.32	1.52±0.34	1.66±0.29
3 Months	7.20±0.50	8.10±0.30	1.80±0.40	0.50±0.53	2.80±1.00	2.10±0.85	4.30±0.95	3.20±0.63	4.30±0.95	3.20±0.63
P Value	0.119**		0.004*		0.002*		0.12**		0.039**	

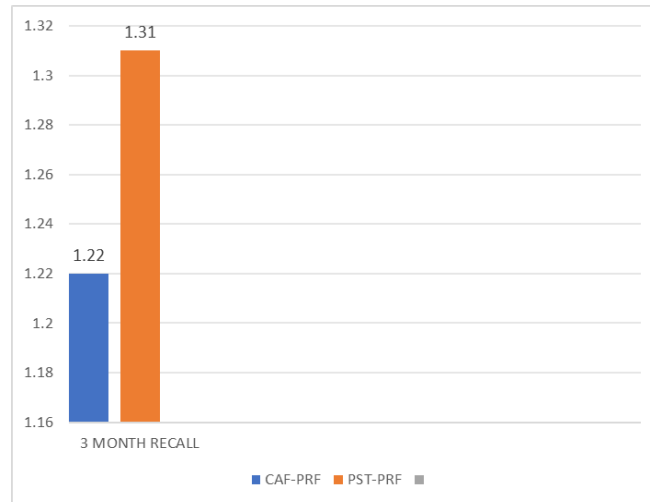
\*P value <0.05 (statistically significant); \*\*P value >0.05 (non-statistically significant)

Table 1 showed intergroup comparison of all the clinical parameter was compared in between group 1 and group 2 at baseline and after 3 months. The intergroup comparison of width of keratinized gingiva (WKG), probing pocket depth (PPD) and Clinical attachment level (CAL) at baseline and 3 months was found to be statistically non-significant in between the groups i.e., Group 1 (pin hole technique with PRF) and Group 2 (CAF with PRF). However. Recession depth (RD) and Recession width (RW) was found to be statistically significant in between Group 1 (pin hole technique with PRF) and group 2 (CAF with PRF) in between time intervals i.e., baseline and after 3 months.

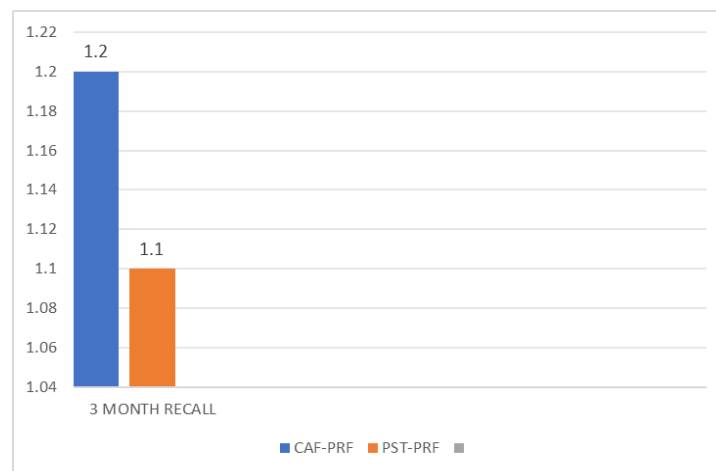
**Table 2:** Intragroup comparison of all clinical parameters in between group 1 and group 2 at baseline and after 3 months

	Width of Keratinized Gingiva (WKG)		Recession Depth (RD)		Recession Width (RW)		Probing Pocket Depth (PPD)		Clinical Attachment Level (CAL)	
	Group 1	Group 2	Group 1	Group 2	Group 1	Group 2	Group 1	Group 2	Group 1	Group 2
Baseline	7.40±0.82	7.80±0.57	2.80±0.84	2.80±0.84	2.04±0.57	2.01±0.57	4.80±0.76	5.00±0.61	1.52±0.34	1.66±0.29
3 Months	3.60±0.89	3.30±0.97	1.20±0.45	1.10±0.22	1.31±0.33	1.22±0.30	2.40±0.55	2.20±0.10	1.23±0.33	1.43±0.27
P Value	0.00*	0.00*	0.00*	0.02**	0.002**	0.00*	0.01**	0.00*	0.14**	0.27**

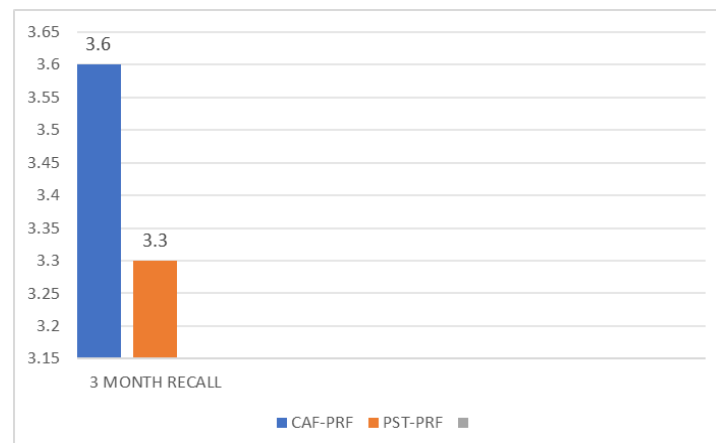
\*P value <0.005 (statistically significant); \*\*P value >0.005 (non-significant)



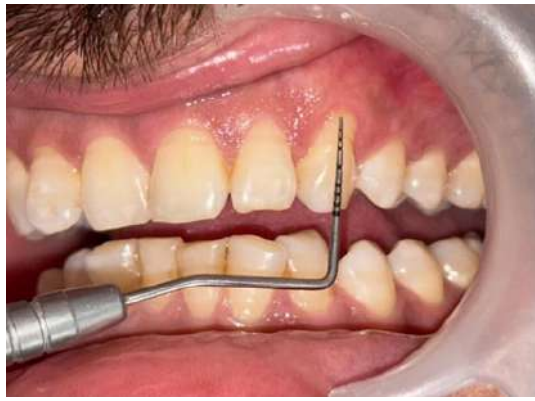**Graph 1:** Comparison of Recession width at baseline and 3 months in Group 1 and Group 2.



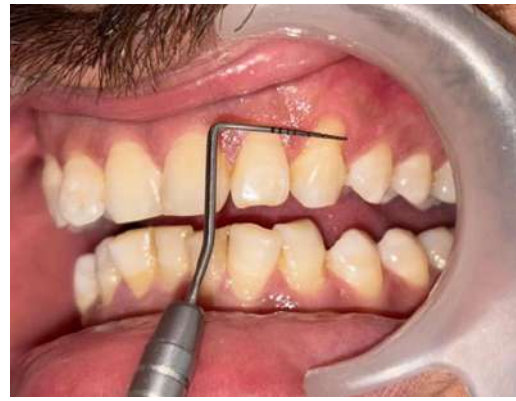**Graph 2:** Comparison of Recession depth at baseline and 3 months in group 1 and group 2.



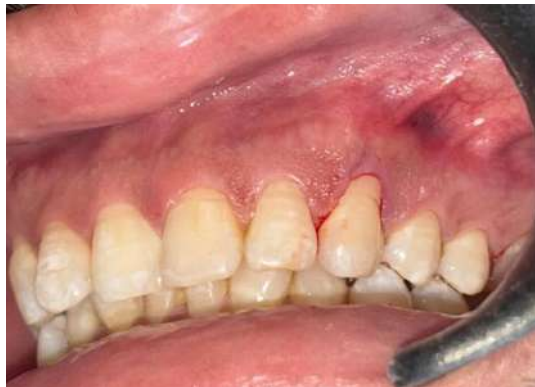**Graph 3:** Comparison of Width of Keratinized Gingiva at baseline and 3 months in group 1 and group 2.



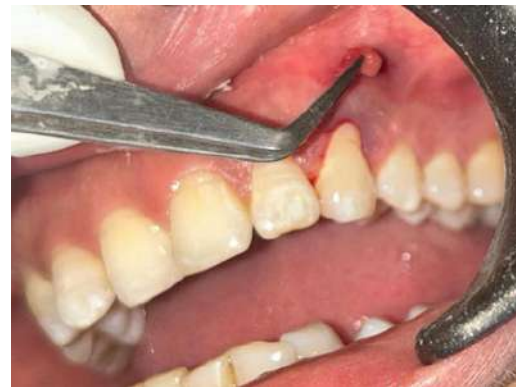Preoperative Recesse



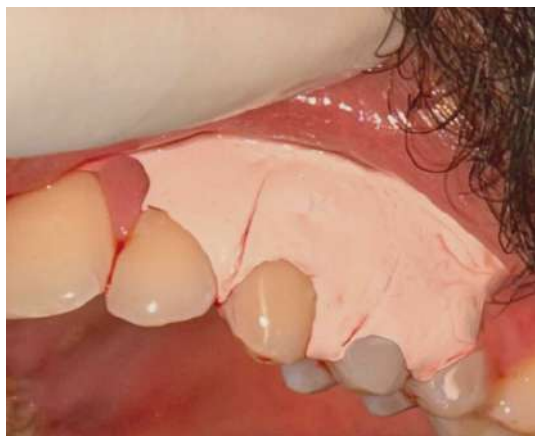Preoperative Recession Depth



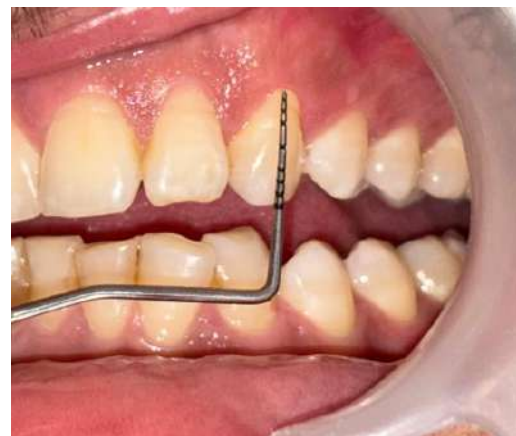Sulcular Incision & Pinhole Incision



Placement of PRF into the Pinhole Site



Coe Pak Placed



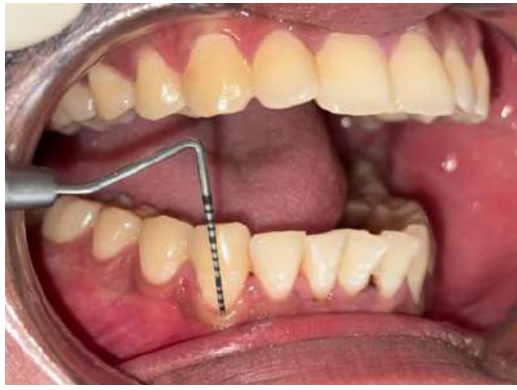3 Month Post Operative Follow Up

**Group 1:** (Test Group) Pinhole Surgical Technique With PRF.

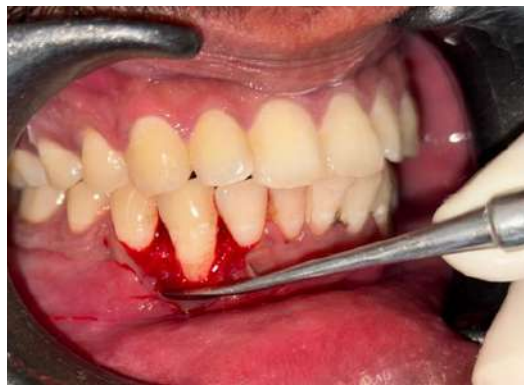In Group I (test group), the baseline score of various clinical parameters decreased after 3 months. This reduction was statistically significant in terms of width of keratinized gingiva, recession depth as indicated by a p-value of <0.005. This suggests that the test group experienced a meaningful reduction in recession depth and gain in width of keratinized gingiva over the 3-month period. However, there was a statistically non-significant values were found in terms of recession width, Probing pocket depth and clinical attachment level as indicated by the p value >0.005.

Similarly, in Group II (the control group), the baseline scores were reduced after 3 months of time interval. This reduction was also statistically significant in terms of width of keratinized gingiva, recession width and probing pocket depth with a p-value of <0.005. This indicates that, the control group also showed a significant decrease in the values over the 3-month period. However, there was statistically non-significant values found in terms of recession depth, clinical attachment level as indicated by the p value >0.005.

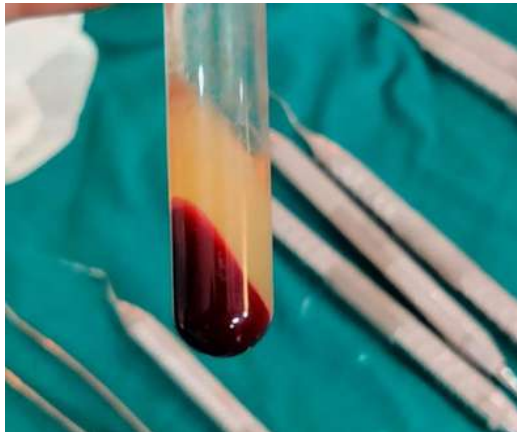Intragroup comparison highlighted that while both techniques were effective, PST consistently showed superior outcomes in terms of root coverage, reduction in recession depth and width, and patient comfort, thereby supporting its effectiveness as a minimally invasive alternative to CAF.



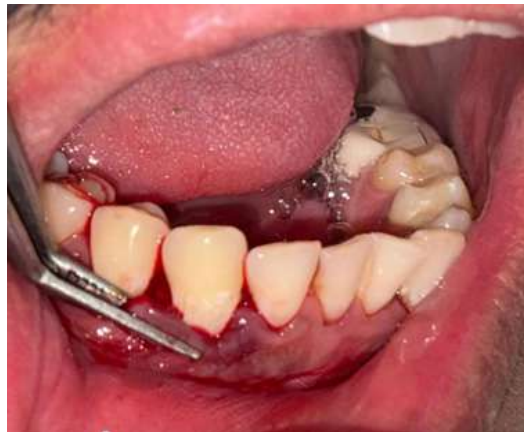Preoperative Recession



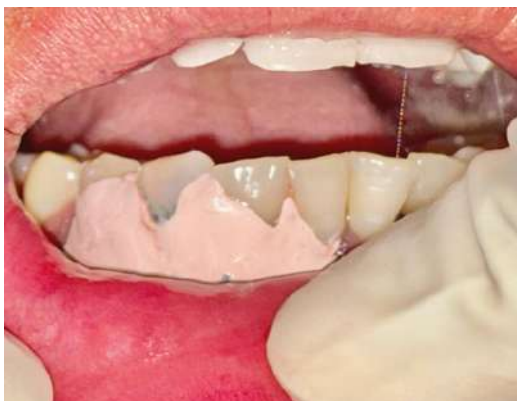Flap Elevation



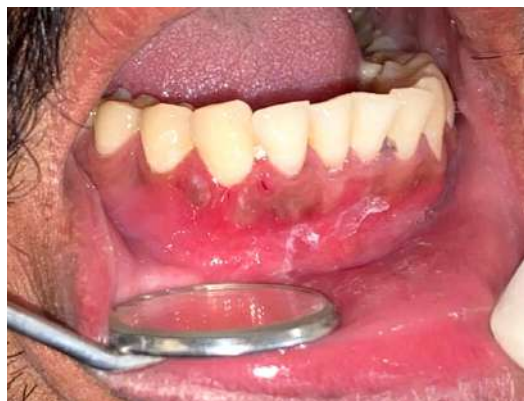PRF Preparation



Coronal Advancement



Coe Pak Placement



3 Month Post Operative Follow Up

**Group 2: (Control Group) Coronally Advanced Flap Technique with PRF.**

## Discussion

Periodontal surgery was aimed only at functional goals for many years but due to advancements and patients aesthetic concern, it has been more concentrated on functional and aesthetic goals. The majority of aesthetic concern in periodontal tissues is associated with Gingival Recessions [7]. Gingival recessions are usually presented to a clinician during patient's aesthetic concern, exposure of the root surfaces leading to dentinal hypersensitivity or problems that are awakened by the aggressive and associated factors. The associated factors include Dehiscence of bone, insufficiency in the keratinized tissue, mal-positioning of the tooth, high frenal attachment and inadequate vestibular depth. The aggravating factors are regressive alterations of the tooth structure by abrasion, abfraction and erosion, Plaque and Calculus accumulation which triggers inflammation, improper or traumatic brushing. Iatrogenic factors such as ill-fitting dentures, traumatic operative procedures, occlusal trauma. The diverse factors include age, gender, piercing, chewing stick trauma [8].

Limited amount of regeneration was observed with conventional technique when quality of healing examined histologically [9,10]. Therefore, various adjunctive agents were tried to accelerate healing and enhance clinical outcome. These adjunctive included root conditioners, enamel matrix protein, recombinant human platelet derived growth factor, etc.

The cost of mucogingival operations may arise when such adjunctive are used. So, when multiple recession defects are present in the aesthetic area of the mouth, patient related considerations hold an utmost importance in selection of surgical technique. Patient compliance, aesthetic appearance, simplicity and cost play a substantial role in the selection of treatment technique.

The coronal advancement of the flap may be recommended in patients with adequate amount of keratinized tissue apical to recession defect. CAF is most beneficial for the treatment of multiple adjacent recession type defects; however, it can also be employed to treat single recession defects. This procedure has been used independently, but has also been used in addition with connective tissue grafts, barrier membranes, acellular dermal matrices, enamel matrix derivatives and platelet concentrate which has shown advantageous clinical outcomes. PRF introduced by Choukroun et al. (2001) is considered as a second-generation platelet concentrate [11]. PRF has shown a proliferative effect on different types of cells such as dental pulp cells, human osteoblasts, human gingival and periodontal ligament fibroblasts, dermal pre-keratinocytes and preadipocytes. The homogeneous 3 dimensional naturally polymerized fibrin network is considered as a healing biomaterial and is used to enhance periodontal regeneration. PRF exhibits a greater expression and release growth factors and matrix proteins at slower pace because of 3-dimensional architecture forming a fibrin network which is composed of adhesive glycoproteins. Autologous PRF is a readily available and inexpensive biomaterial. Recently researchers are trying to explore more beneficial effects of PRF in the form of growth factors through various clinical trials and studies especially for the management of recession defects.

Therefore, the present study was performed clinically to evaluate the effectiveness of Pinhole Surgical Technique versus Coronally Advanced Flap with PRF as an adjunct in the management of gingival recession defect. Clinical parameters such as Probing Pocket depth, clinical attachment level, recession depth, recession width and width of keratinized gingiva thickness were recorded at baseline & after 3 months post operatively. On intergroup comparison, recession width and recession depth were found to be statistically significant in between group 1 and group 2. However, width of keratinized gingiva, probing pocket depth and Clinical attachment level were found to be statistically non-significant in between group 1 and group 2. On intragroup comparison, the test group experienced a meaningful reduction in recession depth and gain in width of keratinized gingiva over the 3-month period. However, there was a statistically non-significant values were found in terms of recession width, Probing pocket depth and clinical attachment level. The control group showed statistically significant reduction in terms of width of keratinized gingiva, recession width and probing pocket depth over the 3-month period. However, there was statistically non-significant results found in terms of recession depth, clinical attachment level.

The result of the present study emphasises that both PST and CAF techniques are consistently effective by showing more superior results for recession coverage defect especially for recession depth and width. Also, patients were comfortable while surgical procedure as it is minimal invasive procedure without any incision with immediate cosmetic outcome. Shibly O, Chao JC et al 2025 conducted a study to compare the treatment of gingival recession defects using either a coronally advanced flap technique and connective tissue graft (CAF + CTG) or the pinhole surgical technique and collagen membrane (PST + CM) [12]. similar results were found in terms of recession depth and width and both the techniques can be used successfully to treat gingival recession. Agarwal MC, Kumar G et al 2020 concluded in case series with 6month follow up that recession depth and width was found with significant result and root coverage was 87% when compared to original study performed by Chao et al where root coverage was found to be 88.4% [13]. Similarly, Al-Barakani, M.S., Al-Kadasi, B., Al-Hajri, M. et al 2024 conducted a study to treat the gingival recession defects with pin hole surgical technique in combination of advanced PRF and found a satisfactory outcome in terms of keratinized tissue width (KTW), recession depth (RD), recession width (RW), and gingival thickness (GT) with follow up time period of 3 months [14].

The addition of PRF in the recession coverage technique has beneficial effect in terms of improvement in soft-tissue wound healing/regeneration and release of more growth factors at the treated site. Pin hole surgical technique overcomes the limitation of coronally advanced flap vertical releasing incisions and elevation of full-thickness flap that compromise the blood supply to the flap, scar formation, and shortening of vestibule. Although the present study showed significant improvement in all the clinical parameters among both the groups but it has certain limitations such as small sample size and shorter duration of follow-up. A larger sample size would be desirable so as to substantiate the results. Long term analysis is needed to determine the stability of the results. Also, PST technique requires specific instrument, trained operator skills and technique sensitive for further improvement while handling the soft tissue in more precised manner.

## Conclusion

Within the limitations of the study, it can be concluded that both Pinhole Surgical Technique with PRF and Coronally Advanced Flap with PRF are effective in the treatment of Miller's Class I and II gingival recession defects.

However, PST demonstrated superior clinical outcomes in terms of recession depth and width, gain in keratinized gingiva, and patient comfort. The minimally invasive nature of PST, combined with the regenerative potential of PRF makes it a promising technique for predictable root coverage and enhanced esthetics. Further long-term studies are required to confirm its stability and broaden its clinical applicability.

## References

1. Chao, J.C. A novel approach to root coverage: the pinhole surgical technique. *International Journal of Periodontics & Restorative Dentistry* 2012; 32(5):521-31.
2. Bellver-Fernández R, Martínez-Rodríguez AM, Gioia-Palavecino C, Caffesse RG, Peñarrocha M. Surgical treatment of localized gingival recessions using coronally advanced flaps with or without subepithelial connective tissue graft. *Med Oral Patol Oral Cir Bucal*. 2016;21(2):e222-8.
3. Moka LR, Boyapati R, Srinivas M. Comparison of coronally advanced and semilunar coronally repositioned flap for the treatment of gingival recession. *Journal of clinical and diagnostic research: JCDR*. 2014;8(6): ZC04.
4. Pilloni A, Paolantonio M, Camargo PM. Root coverage with a coronally positioned flap used in combination with enamel matrix derivative: 18-month clinical evaluation. *J Periodontol* 2006; 77:2031-2039.
5. Aroca S, Keglevich T, Barbieri B, Gera I, Etienne D. Clinical evaluation of a modified coronally advanced flap alone or in combination with a platelet rich fibrin membrane for the treatment of adjacent multiple gingival recessions. A 6-month study. *J Periodontol* 2009; 80:244-252.
6. Mihaylova Z, Mitev V, Stanimirov P, Isaeva A, Gateva N, Ishkitiev N. Use of platelet concentrates in oral and maxillofacial surgery: an overview. *Acta Odontol Scand*. 2017;75(1):1-11.
7. A.L. Dumitrescu, Liviu Zetu, Silvia Teslaru. *Aesthetic periodontal Therapy-Root Coverage*. Novascience Publishers: pp.1-29.201.
8. Nguyen-Hieu T, Ha Thi BD, Do Thu H, Tran Giao H. Gingival recession associated with predisposing factors in young Vietnamese: a pilot study. *Oral Health Dent Manag*. 2012; 11(3):134-44.
9. Weng D, Hurzeler MB, Quinones CR, Pechstadt B, Mota L, Caffesse RG. Healing patterns in recession defects treated with ePTFE membranes and with free connective tissue grafts. A histologic and histometric study in the beagle dog. *J Clin Periodontol* 1998; 25:238-245.
10. Gottlow J, Nyman S, Karring T, Lindhe J. Treatment of localized gingival recessions with coronally displaced flaps and citric acid. An experimental study in the dog. *J Clin Periodontol* 1986; 13:57-63.
11. Dohan Ehrenfest DM, Del Corso M, Diss A, Mouhyi J, Charrier JB. Three-dimensional architecture and cell composition of a Choukroun's platelet-rich fibrin clot and membrane. *J Periodontol* 2010; 81:546-55.
12. Shibly O, Chao JC, Albandar JM, Almhadi N, Al-Sabbagh M. Treatment of Gingival Recession Using the Pinhole Surgical Technique with Collagen Membrane Vs Coronally Advanced Flap Technique with Connective Tissue Graft: A Split-Mouth Randomized Clinical Trial. *Compend Contin Educ Dent*. 2025;46(1):35-41.
13. Agarwal MC, Kumar G, Manjunath RGS, Karthikeyan SSS, Gummaluri SS. Pinhole Surgical Technique - A Novel Minimally Invasive Approach for Treatment of Multiple Gingival Recession Defects: A Case Series. *Contemp Clin Dent*. 2020;11(1):97-100.
14. Al-Barakani, M.S., Al-Kadasi, B., Al-Hajri, M. et al. A comparative study of the effects of advanced platelet-rich fibrin and resorbable collagen membrane in the treatment of gingival recession: a split-mouth, randomized clinical trial. *Head Face Med* 2024;20: 41.